

Possible Cardiotoxic Effects of Vanadium

Parveen Parkash¹ and Anita Gupta²

Introduction :

Vanadium, a ubiquitous element, is physiologically and pharmacologically an active substance and is present in most of mammalian tissues Jandhala and Hom, 1983). Large corpus of information exists on the mode of action of vanadium on cardiac muscles (Jandhala and Hom, 1983., Solaro et al, 1980), but the basis of pharmacological lesion underlying its cardiac toxicity is still poorly understood. Except for the solitary report of Lewis (1958) to best of our knowledge no information exists on the effect of vanadium on the functioning of heart as shown by electrocardiography.

Large amounts of vanadium are released into atmosphere by combustion of fossil fuel (Vouk, 1979) and due to rapid industrialisation its environmental concentration is reported to be increasing (Goldberg et al, 1974., Jaffe and Walters, 1977., Vouk, 1979). This necessitates the monitoring of its environmental and occupational hazards. In the present study cardiac side effects of vanadium, as revealed through ECG has been investigated in rabbits, since the electrocardiogram of rabbit resembles with of man in essential details (Weisborth et al, 1974).

Materials and Methods :

Fifteen healthy male albino rabbits,

weighing 2-2.5 kg each, were procured from Hissar Agriculture University, Haryana. They were housed in steel cages and provided a diet of commercial rabbit pellets and water ad-libitum. The rabbits were observed for two weeks before the study was conducted to allow adaptation to the vivarium environment and to eliminate sick animal, if any. After this these rabbits were divided into three groups of five each. Before ECG recordings, rabbits of first group were anaesthetized with intraperitoneal injection of pentobarbitone sodium (35 mg/Kg of body weight). Electrocardiographic recordings were obtained on ink-jet polygraph with standard limb lead II using fine needle electrode placed subcutaneously and attached to ECG amplifier, adjusted for recorder deflection of 1 cm/mV before vanadium treatment for five minutes. Bolus injection of intravenous (i. v.) vanadium (200 mg/Kg) was given in the ear vein of rabbits. Sodium vandate was dissolved in distilled water (1 mg/ml) and volume of dose was kept 0.2 ml. After this their ECG was recorded for half an hour with a paper speed of 50 mm/sec. Afterwards, ECG records were analysed for R-R interval calculations and thereby heart rate changes. Amplitude and topographic changes were analysed for individual rabbit separately.

For serum potassium analysis, same dose of vanadium was injected similarly in

1. Lecturer, Dept. of Physiology,
2. Research Fellow, Dept. of Biochemistry, Medical College, Amritsar.

the right vein of rabbits of 2nd group. Blood samples were taken before and after 1, 2, 3, 5, 8, 10, 15 and 20 minutes intervals of vanadium treatment from left vein and assayed for serum potassium levels (Reiner, 1974).

In third group of rabbits same volume of distilled water was injected intravenously to check the effect of volume if any. The rabbits were kept under observation for 7 days. No rabbit developed apparent morbidity. All the p-values were obtained by Wilcoxon's two-sample test (one tailed). p-values less than 0.05 were regarded as statistically significant.

Results :

P-wave remained distinct without any change in wave form throughout the experiment. During first 2 min, QRS complex depicted slight decrease in amplitude. However, after this amplitude of the complex

increased and was maintained for 8 min. Later, amplitude of this complex regressed again. The amplitude trend of T-wave was similar to that of QRS complex i.e., initial fall, then increase which was maintained for 8 min, maximum being at 3rd min and final fall (fig. 1). Wave form revealed peculiar changes i.e., it became peaky, long and tented during 3rd minute and gave the appearance of biphasic configuration at the end of 10th min. Raised J point and merger of ST-segment with T-wave was clear at the 3rd min interval (fig. 1). This got converted into another form i.e., ST-segment with convexity upward by the end of 10th min. Rhythm was regular during record. Heart rate before vanadium treatment was 343 ± 32.67 beats/min, R-R interval being 0.175 ± 0.018 sec. Heart rate and R-R interval after 2nd min of i.v. vanadium revealed a fluctuating falling trend. The fall in the heart rate was statistically significant ($p < 0.05$) at 2, 8, 10 and 15 min interval.

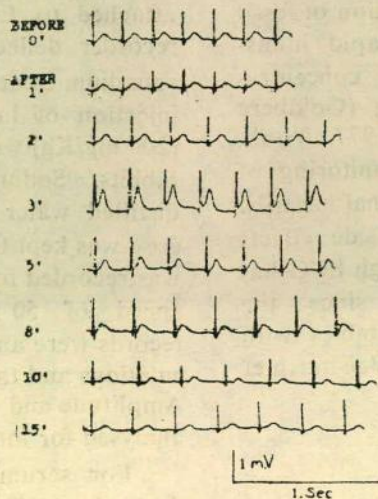


Fig.1 Showing changes in ECG following intravenous vanadium in rabbit

Possible Cardiotoxic Effects of Vanadium

Table 1 : R-R interval and Heart rate changes following intravenous vanadium administration in rabbits.

Interval (Minutes)	R-R interval (Sec)	Heart rate beats/min	Percentage change of heart rate
0	0.175 ± 0.018	343 ± 32.67	—
1	0.176 ± 0.016	341 ± 36.02	0.58
2	0.223 ± 0.025	269 ± 25.32	21.57
3	0.206 ± 0.023	291 ± 31.89	15.16
5	0.215 ± 0.022	279 ± 30.26	18.66
8	0.233 ± 0.020	257 ± 24.72	25.07
10	0.253 ± 0.027	237 ± 22.98	30.90
15	0.241 ± 0.025	248 ± 26.14	27.70
20	0.192 ± 0.012	309 ± 32.14	9.91

n=5

Serum potassium levels started increasing after i.v. injection of vanadium and were statistically significant ($p < 0.05$) at 8, 10 and 15 min interval, maximum being

7.02 ± 0.32 mEq/L 10 min (Tab. 2) later changes in levels were statistically insignificant.

Table 2. Serum potassium levels after intravenous vanadium administration in rabbits (mEq/L).

Control	Time after intravenous injection of vanadium in min.							
0	1	2	3	5	8	10	15	20
5.04 ± 0.29	4.98 ± 0.30	5.08 ± 0.35	5.07 ± 0.27	4.79 ± 0.29	5.45 ± 0.28	7.02 ± 0.32	5.97 ± 0.31	4.87 ± 0.26

n=5

Discussion :

During record of half an hour three phases of myocardial insufficiency first in the form of voltage reduction portraying initial ischemic changes, second in the form

of raised J point and merged ST segment with Tall T-wave reflecting second phase of myocardial insufficiency culminating into third phase of ischemic changes as depicted through low voltage ECG coupled with ST-segment showing convexity upward

suggest vasoconstrictive effect of different grades on coronaries. The potent vasoconstrictive action of vandate in vitro as well as in intact animals has already been reported (Borchard et al, 1981. Hudgins and Bond, 1981., Ozaki and Urakawa, 1980). However, the form of observed myocardial insufficiency is different from that of Lewis (1958) who reported ST-segment depression. The present discrepancy could be due to dose or route differences. Amplitude changes of ECG segment suggest that vanadium can modulate cardiac contractions (Solaro et al, 1980). Vanadium decreased heart rate progressively. This goes parallel with the report of (Inciarte et al, 1980), where intravenous infusion of vanadium resulted in decreased heart rate in dogs. Variation in the amplitude of T-wave suggest that vanadium does affect the serum potassium levels (Currens and Crawford, 1950). This has been further corroborated through serum potassium analysis. This is complementary to reported effect of vanadium on potassium ions (Inciarte et al, 1980 and Kumar and Corder, 1980). The present T-wave alterations also suggest changes in the levels of circulating catecholamines (Lepeschkin, 1950).

This suggests that mechanism of action of vanadium involves chain of events whose initial steps may be dependent on the presence of vanadium but later on these are self perpetuating but with some differences from the initial events. However, the significance of cardiac changes observed in present study for toxicology and genesis of cardiac disease need further investigations.

References :

1. Borchard U., Greffe K., Hafner D., Noack E., Rojsathaporn K (1981) : Effect of vandate on heart and circulation. *Jour. Cardiovasc. Pharmacol*, 3, 510.
2. Currens J. H., and Crawford J. D, (1950) : Electrocardiogram and disturbances of potassium metabolism. *N. Engl. Jour, Med*, 243, 843.
3. Goldberg E.D., Griffin J.J., Hodge V., Koide M and Windom H (1974): Pollution history of the Savannah River Estuary. *Environ, Sci. Technol*, 13, 588.
4. Hudgins P.M. and Bond G.H. (1981): Alteration by vandate of contractility in vascular and intestinal smooth muscle properties. *Pharmacol*, 23, 156.
5. Inciarte D.J., Steffen R.P., Dobbins D.E., Swindall B.T., Johnston J and Haddy F.J. (1980) : Cardiovascular effects of vandate in dog. *Am. Jour. Physiol*, 239, H47.
6. Jaffe D. and Walters J.K. (1977) : Intertidal trace metal concentrations in some sediments from the Humber Estuary. *Sci. Total. Environ*, 7, 1.
7. Jandhala B.S., and Hom G.H. (1983): Physiological and pharmacological properties of vanadium. *Life. Sciences*, 33, 1325.

Possible Cardiotoxic Effects of Vanadium

8. Kumar A and Corder C.N. (1980) : Diuretics and Vasoconstrictor effect of sodium orthovanadate on the isolated perfused rat kidney. *Jour. Pharmacol, Exper, Therap*, 213, 85.
9. Lepeschkin E (1950) : Electrocardiographic observations on the mechanism of the electrical alternans of heart. *Cardiologia*, 16, 278.
10. Lewis C.E. (1958) : The biological actions of vanadium on the excretion of 5-hydroxyindolacetic acid and amino acids and the ECG of the dog. *Arch. Ind. Health*, 20, 455.
11. Ozaki H and Urakawa N (1980) : Effects of vandate on mechanical responses and Na-K pump in vascular smooth muscle. *Eur. Jour. Pharmacol*, 68, 339.
12. Reiner M (1974) : Standard methods of clinical chemistry, vol. I. Academic Press, New York, 102.
13. Solaro R J., Holroyde M.J., Wang T., Matlib M.A., Grupp I., Grupp G and Schwartz A (1980) : Effect of vandate on biochemical and contractile properties of rabbit heart. *Jour. Cardiovas. Pharmacol*, 2 (4), 445.
14. Vouk V (1979) : In Handbook on toxicology of metals. Elsevier/North Holland Biomedical Press Amsterdam. 659,
15. Weisborth S.H., Flatt R.R. and Kraus A.L. (1974) : Biology of laboratory rabbit, Academic Press, INC, New York, 57.